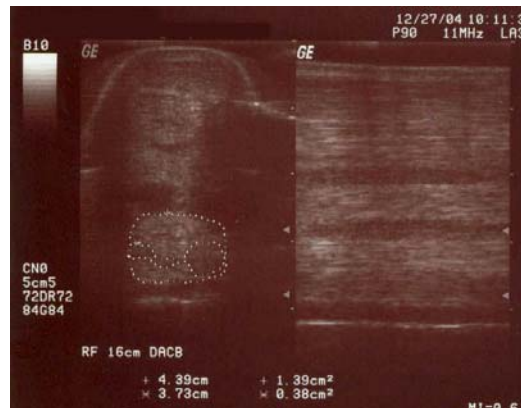


Case 122804-01: 11 Year Old Dressage Horse -Suspensory Ligament Desmitis with Avulsion Fractures

On December 27, 2004 an 11 year-old Warmblood gelding presented on referral for evaluation of a right front limb lameness of 2 months duration. The referring veterinarian had diagnosed moderate suspensory ligament desmitis. He localized the lesion to the body of the ligament and referred the horse for intralesional therapy.

Physical examination found the horse to be 2/5 lame in the right front limb. Ultrasound evaluation of the right front limb revealed a moderate origin desmitis with the presence of small bony irregularities suggestive of avulsion fractures, as well as additional changes observed in the body. The largest area of damage was localized to a region 14 to 16 cm distal to the accessory carpal bone (Fig 1).

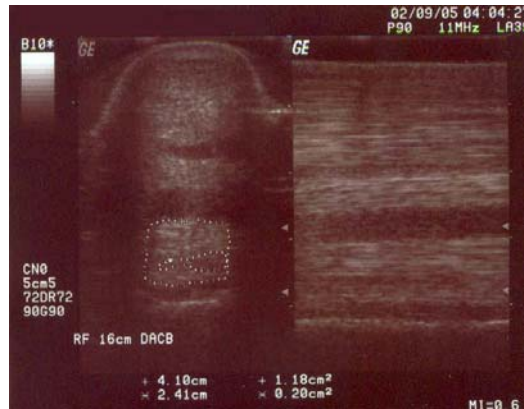


**Figure 1: Suspensory Lesion, 16 DACB
December 27, 2004**

An 18.5 gram sample of subcutaneous adipose tissue was harvested from the right gluteal region and submitted for stem cell recovery.

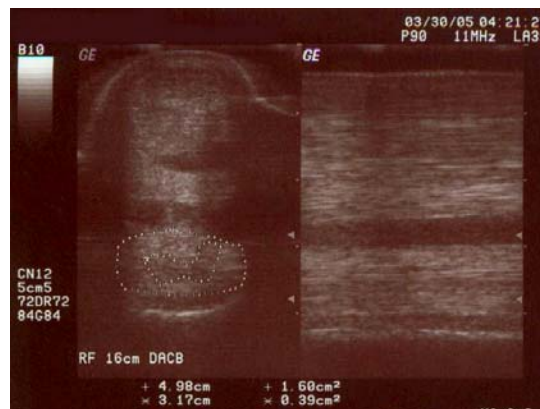On December 29, 2004, 4.2 million viable cells were injected into the lesion ultrasound guidance. The patient was discharged with instructions to stall rest for 14 days and then to follow this with gradual increases in hand walking.

Physical examination on February 9 (6 weeks following stem cell therapy) found the horse to be improved to a lameness score of 1/5. Ultrasound evaluation of the affected region revealed moderate increases in echogenicity in the body and origin lesions, with improved linearity of patterning on longitudinal examination of the ligament (Fig 2). The patient's rehabilitation regimen was increased to include daily hand walking and walking under saddle.



**Figure 2: Suspensory Lesion, 16cm DACB
February 9, 2005**

On March 30, 2005 physical examination showed the horse to be increasingly improved, with only a 1/5 lameness in the right front limb noted when circling to the left. Ultrasound evaluation revealed generalized improvement in fiber pattern and echogenicity throughout the affected region (Fig 3). In the region 10 to 14 cm distal to the accessory carpal bone, short random linear echoes were still present with a slight increase in diameter still evident.



**Figure 2: Suspensory Lesion, 16 cm DACB
March, 30, 2005**

With instructions to return to walking for 4 additional weeks and then adding a trot sequence to the rehabilitation regimen, the horse was returned back to the supervision of its normal attending veterinarian.

Reports from the attending veterinarian on July 29 revealed resolution of the original lesion with only minute residual echoes present and physical examination found the horse to be sound at the walk and the trot. The owner and patient were cleared to return to their previous level of competition in August of 2005 (8 months following stem cell therapy) and have been successfully showing since that time.